

A complicated case of chronic Pan Colitis

What is Pan Colitis or IBD?

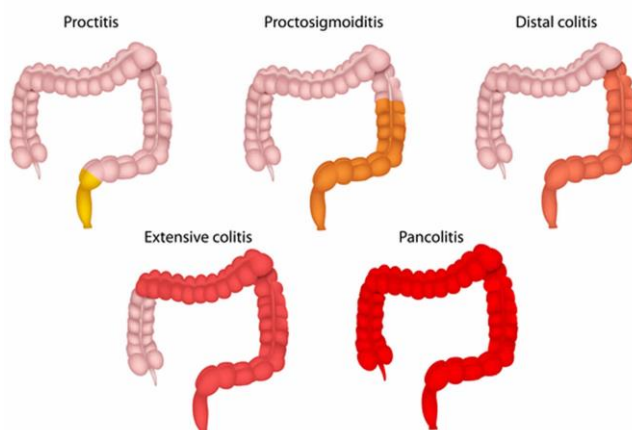
Pancolitis is a form of inflammatory bowel disease characterized by widespread inflammation affecting the entire colon. It can result in various symptoms, including abdominal pain, diarrhea, weight loss, and fatigue.

Abstract

A 27 year old male patient presented with gradual weight loss, pain abdomen, regular watery stool mix with blood , appetite poor, loss of energy, mental irritability, he was suffering from more than 18 months.

Causes of Pan Ulcerative Colitis or Pancolitis

TYPES OF ULCERATIVE COLITIS



The exact cause of pancolitis is still unknown. As with other inflammatory bowel diseases, pancolitis can be caused by genes. The environment also plays an important role. Anti-inflammatory drugs or other sorts of medication can also increase the risk. One of the most common factors is a high-fat diet. Other factors include:

- Genetic predisposition
- Abnormal reaction from the digestive system to intestine bacteria
- Abnormal immune response
- Unknown triggers (virus, bacteria, stress, or diet)

In certain cases, when a person doesn't get treatment for mild forms of UC, the condition can worsen and result in pancolitis. Around 20% of people who have ulcerative colitis will have pancolitis. It is also believed that stress and anxiety can lead to UC and pancolitis. Stress and anxiety can trigger ulcers, causing pain and discomfort. But these factors don't actually cause pancolitis.

He was treated by modern medicine (allopathic) at renowned hospital in Kolkata but no significant response. Then he decide for homeopathy treatment.

Test report and histopathology report attached

RAMAKRISHNA MISSION SEVA PRATISHTHAN

99, SARAT BOSE ROAD,
KOLKATA - 700026
Phone No: 033-2475-3636

Date: 25-Sep-2021
Name: Mr. SUSOVAN MALAKAR
Age: 26 Y
Sex: M
Patient ID: 2021090137

Hospital ID: S/005870/21
Study: COLONOSCOPY
Examined By: Dr. S BHATTACHARJEE
Ref By: Dr. D J BHOWMICK



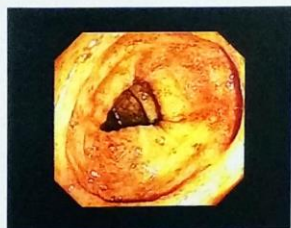COLONOSCOPIC FINDINGS:

Poor Bowel Preparation.

Seen upto Caecum.

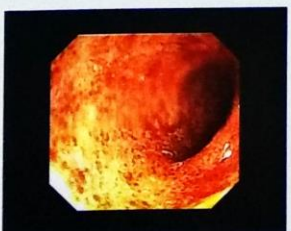
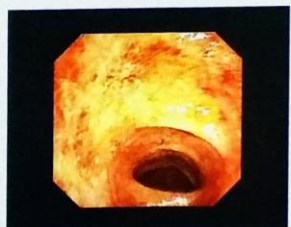Mucosa of the entire colon is congested eroded friable with multiple superficial and deep ulcers.

There is loss of vascular pattern.



Biopsy taken for HPE.

IMPRESSION : Pan Colitis. (? IBD)





RAMAKRISHNA MISSION SEVA PRATISHTHAN

99, SARAT BOSE ROAD, KOLKATA-700 026, PHONE : 2475-3636

NAME	SUSOVAN MALAKAR	HISTO.NO.	2197/21
AGE	26 YEARS	SEX	MALE
BED NO.	OPD	MRD/OPD NO.	S/5870/21
REF.DR.	DR.D.J.BHAUMICK	DATE OF RECEIPT	25-09-2021

HISTOPATHOLOGY REPORT

SPECIMEN: Colonoscopic biopsy. Indication-Pancolitis to ?? UC

GROSS: Multiple grey brown tissue bits are received altogether measures 0.4 x 0.3 x 0.1 cm. All material embedded in one block.

MICROSCOPIC EXAMINATION: Large intestinal mucosal biopsies reveal ulcer with granulation tissue, prominent crypt abscess & markedly increased mixed inflammatory cell infiltrate in the lamina propria. Crypt architecture distortion is severe and regenerative changes are prominent.

Features are those of ulceration with severe active & chronic inflammation of the colon.

INTERPRETATION:

Colonic biopsy: ulceration, severe active and chronic colitis.

Comments: If typical clinical and colonoscopic features of inflammatory bowel disease are noted, morphology would be consistent with severe active phase of inflammatory bowel disease.

Dr. P. Ray
MD (Path)
FRC Path, CCT (UK)

Dr. Soumit Dey
MD (Path)
DNB, FRC Path (London)

Created by:mkd
Dated: 04-10-2021

2.

HOMEOPATHIC APPROACH FOR PAN COLITIS

Homeopathic treatment based on symptoms similarity and individualistic approach

General History

Appetite- poor

Desire : Cold water

Sleep- disturbed #

Stool- frequent, uncontrolled, watery mixed with blood

Urine- Normal

Perspiration- +

Gas & Acid- ++ and patien

Abdominal pain++ fullness

last 1.5 years

Complexion- fair

Body: lean thin emaciated

Face- Anxious

Treatment

Date 12/09/22

Phosphorus 30/ 6dose + Rubrum mur 200/ 24 dose

27/09/22 Argentum nit 30/01 d + PL 24 dose

01/10/22 PL 200/ 30 Dose + Carsinosin 200/1d

13/10/22 H.varginica mt.. 10drpos TDS

30/10/22 MERC SOL 30/4D

23/11/22 MERC SOL 200/1DOSE

07/01/23 RUBRUM 200

26/01/23 PL 200/30D Significant improvement no cramp, no mucous stool, no blood

15/02/23 MERC SOL 32/ 30DOSE better than before no problem

OBSEVATION TILL 07/04/24

NO PROBLEM REAPPEAR HEALTH IMPROVE , QALITY OF LIFE IMPROVE